

Reticular Lichen Planus in Young Female: Rare Case Study

ROHAN SACHDEV*, KRITI GARG and SEKHAR MUKHERJEE

Dept of Oral Medicine and Radiology, Rama Dental College, Kanpur, India.

Abstract

Lichen planus is a chronic autoimmune disorder of mucosa and skin, mainly females in their forty to sixty years and rare in young age group. Etiology is still unknown; certain triggering factors include mental stress, medicines and systemic disorders. Oral Lichen planus is a painful disorder; mainly involve the buccal mucosa of the oral cavity. The reticular pattern is most common while atrophic and erosive type of oral lichen planus are less common. Here we present a rare case of a reticular lichen planus involving the right buccal mucosa and tongue of 18 years old female patient without any cutaneous lesions.



Article History

Received: 26 April 2019
Accepted: 02 August 2019

Keywords

Buccal Mucosa; Chronic;
Corticosteroids; Female;
Immune Mediated; Lichen Planus;
Oral Cavity; Painful;
Reticular; Squamous Epithelium;
Tongue; Unilateral.

Introduction


The term lichen originates from greek signifies moss while planus signifies no raised surface. Erasmus Wilson in 1869 gave the term Lichen planus.^{1,2} Lichen planus (LP) is a chronic disease of skin and mucosa, present mainly squamous epithelium layer of body, with a occurrence rate of 1.3% with a women in majority.³ Oral lichen planus has most often present in age group of 35-65 years, ratio of occurrence females to males(1.5:1).⁴ Oral lichen planus is rarely present in children, very few reports on this have present are present [records from PubMed Cental only 3 cases of reticular

lichen planus have been reported among 8 and 10 years old children from 2010 to 2019.⁵ Oral lichen planus has been present in six clinical appearances including reticular, atrophic, plaque, papular, erosive and bullous types. Common sites of involvement are the buccal mucosa, dorsum of the tongue and rarely of gingiva.⁶ The aetiology of the oral lichen planus is idiopathic; appears to be multi-factorial in few patients. Viruses, genetic factors and modern way of living can be important factor in development of disease along with, an inborn error in the metabolism of glucose-6-phosphate dehydrogenase shortage, and long present unusual glucose metabolism with

CONTACT Rohan Sachdev ✉ drohansachdev@live.com 📍 Dept of Oral Medicine and Radiology, Rama Dental College, Kanpur, India.



© 2019 The Author(s). Published by Enviro Research Publishers.

This is an  Open Access article licensed under a Creative Commons license: Attribution 4.0 International (CC-BY).

Doi: <https://doi.org/10.12944/EDJ.01.01.04>

glucose intolerance.^{7, 8, 9} This disorder starts by an unusual cell mediated immune reaction to T4 and T8 lymphocytes in the basal epithelial layer. Auto generated killer CD8 + T-cells activate the degradation of oral epithelial layer.¹⁰ We reporting a case study of reticular lichen planus, in 18years old female which is a rare occurrence.

Case Report

An 18 years old female patient reported with a chief complaint of a whitish patch on right cheek and tongue since 1 year. Patient gave a detailed history of burning sensation of her cheek and tongue which leads to difficulty in eating and swallowing of food for 6 months. The patient reported discomfort on consumption of spicy or acidic food and drinks.

No cutaneous lesion was visible. The patient was normal and was not taking any systemic medication. She was a non-smoker and non-alcoholic. Upon intraoral examination very poor oral condition and Wickhams striae seen on the right buccal mucosa, present with relation to 44 to 47 regions and right lateral border of tongue.[Fig-1,2]

Based on the clinical examination, case was provisionally diagnosed as reticular lichen planus. Hematological examination and biochemistry yielded negative results. Biopsy was performed and the H&E stain analysis showed diagnostic features of lichen planus. Then, patient given a regimen of anti-oxidant twice/day (Cap. Lycostar®) and topical cortico-steroid triamcinolone acetonide 0.1%

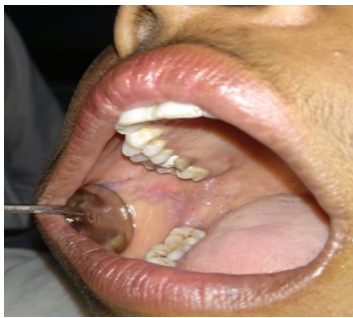

Fig. 1: Reticular pattern lichen planus present on right buccal mucosa

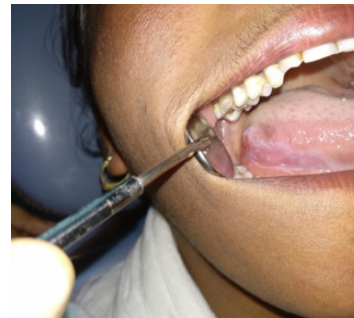

Fig. 2: Reticular pattern present on right side of tongue

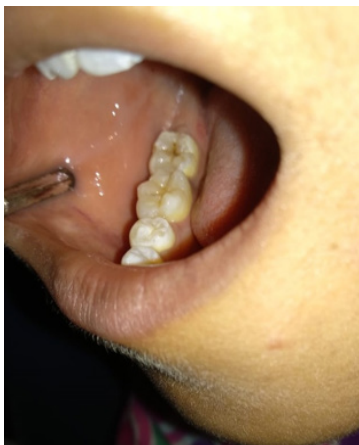

Fig. 3: Complete remission of lichen planus on right buccal mucosa after six months

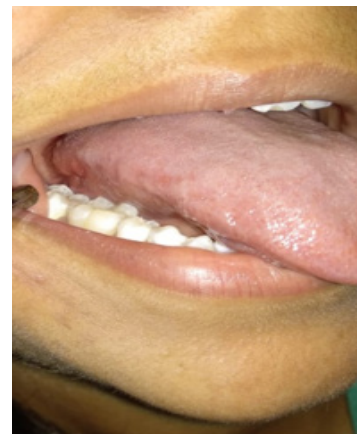

Fig. 4: Complete remission of lichen planus on right side tongue after six months

three times/day (Tess ointment®) for seven days. The patient was instructed not to eat spicy food and take a healthy fresh fruit and vegetables full diet. After 1-week recall visit, the patient presented with improvement in the burning sensation. Oral hygiene instructions were given to patient and she was recalled after 15 days for follow up The recovery was satisfactory and following the duration of two months the striae had healed completely and the patient was appeared normal.[Fig-3,4] On further follow up of 3months interval till six months no incident of repetition was seen.

Discussion

Oral lichen planus (OLP) occurrence rate is between 0.6 - 2.5 % the mainly appear in the age range 35 to 65 years, with women in majority.^{10,11,12} In the present case patient age was 18years, which is rare to the presence of oral lichen planus. It is a chronic, inflammatory disorder that affects mainly mucosal and skin layers of the body.¹³ The commonest type of oral lichen planus is reticular form which appears as white keratotic striae keratotic ; known as Wickham's striae with reddened outline.¹⁴ Buccal mucosa(62%) affects mainly, followed by the alveolar mucosa (19%), tongue (14%) and lips (2%).^{15,16} In our presented case cheek mucosa and right border of tongue was involved which supports the percentage of occurrence in the oral mucosa.

Oral lichen planus can be diagnosed clinically in classic reticular pattern, although biopsy is often

required to confirm the diagnosis.^{16,17} Oral lichen planus can be differentiated with cheek bite, homogenous leuoplakia and pseudomembranous candidiasis.^{18,19} Various treatment modalities are in use to treat oral lichen planus; topical corticosteroids like .0.05% betamethasone and 0.10% triamcinolone acetonide ointment always be the primary choice of medication.^{20, 21} Patient can be advised to maintain good oral hygiene, during the active course of disease. However, since some types of oral lichen planus carries a high converting possibility into malignancy, henceforth it needs immediate medication with regular reexamination.²²

Conclusion

Lichen planus is a chronic immune-mediated disorder present on the buccal mucosa and gingiva; often painful. In the modern era because of stressful lifestyle especially among young people, increasing the risk of occurrence of oral lichen planus. Clinician must explain the re-occurrence pattern and alarming sign of exacerbation to patient and also keep a long term follow up of all intra oral lesions in histologically confirmed cases of oral lichen planus to evaluate the malignant potential.

Acknowledgement

We acknowledge the patient and her parents for co-operation.

Source Of Funds

None

References

1. Pauly G, Kashyap R, Kini R, Rao P, Bhandarkar G. Reticular oral lichen planus: The intra-oral web – A case report. *Gülhane Tıp Derg* 2017;59: 28-31.
2. Eisen D, Carrozzo M, Bagan Sebastian JV, Thongprasom K. Oral lichen planus: clinical features and management. *J Oral Dis*. 2005; 1 (6): 338–349.
3. Boorghani M, Gholizadeh N, Taghavi Zenouz A, Vatankhah M, Mehdipour M. Oral lichen planus: Clinical features, etiology, treatment and management; A review of literature. *J Dent Res Dent Clin Dent Prospects* 2010;4:3-9.
4. Khandelwal V, Nayak PA, Nayak UA, Gupta A. Oral lichen planus in a young Indian child. *BMJ Case Rep* 2013:1-3.
5. Moliaoglu N. Oral lichen planus: a review. *Br J Oral Maxillofac Surg* 2000;30:370–7.
6. Gujjar P, Zingade J, Patil S, Hallur J. Recent Update on Treatment Modalities of Oral Lichen Planus- A Review. *IJSS Case Reports & Reviews* 2015; 2(4):40-44.
7. Vijay P, Pardhe N, Singhal I, Punga R, Singh

- H. Oral Lichen Planus: A Case Report. *Int J Oral Health Med Res* 2016;3(3):54-55.
8. Eltohami YI, Alim NE, Abuaffan AH. Lichen Planus of the Tongue Case Report. *EC Dental Science* 8.5 (2017): 183-185.
 9. Edwards PC, Kelsch R. Oral Lichen Planus: Clinical Presentation and Management. *Can Dent Assoc* 2002; 68(8):494-499.
 10. Usatine RP, Tinitigan M. Diagnosis and Treatment of Lichen Planus. *Am Fam Physician*. 2011;84(1):53-60.
 11. Neville BW, Danm DD, Allen CM, Bouquet JE, editors. *Oral and Maxillofacial Pathology*. 3rd ed. India: Elsevier Publishers; 2009. p. 782-788
 12. Jontell M, Holmstrup P. Red and white lesions of the oral mucosa. In: Green berg MS, Glick M, Ship JA, editors. *Burket's Oral Medicine*. 11th ed. Hamilton: BC Decker Inc; 2008. pp. 90–1.
 13. Rajendran R. Diseases of the skin. In: Rajendran R, Sivapathasundharam B. editors. *Shafer's Textbook of Oral Pathology*. 6th ed. India: Elsevier, a Division of Reed Elsevier India Private Limited; 2009. p. 799-803
 14. Ismail SB, Kumar SK, Zain RB. Oral lichen planus and lichenoid reactions: Etiopathogenesis, diagnosis, management and malignant transformation. *J Oral Sci*. 2007; 49:89-106.
 15. McCartan BE. Psychological factors associated with oral lichen planus. *J Oral Pathol Med*. 1995; 24:273-5.
 16. Andreasen JO. Oral lichen planus. A clinical evaluation of 115 cases. *Oral Surg Oral Med Oral Pathol* 1968;25:31-42.
 17. Varghese SS *et al.*, Epidemiology of Oral Lichen Planus in a Cohort of South Indian Population: A Retrospective Study. *J Cancer Prev* 2016;21:55-59
 18. Van der Meij EH, Van der Waal I. Lack of clinico-pathologic correlation in the diagnosis of oral lichen planus based on the presently available diagnostic criteria and suggestions for modifications. *J Oral Pathol Med*. 2003;32:507-12
 19. Krupaa RJ, Sankari SL, Masthan KM.K, Rajesh E. Oral lichen planus: An overview. *Dent Sci* 2015;7(5):158-161.
 20. Farhi D, Dupin N. Pathophysiology, etiologic factors, and clinical management of oral lichen planus, part I: Facts and controversies. *Clin Dermatol*. 2010;28:100–8. [PubMed]
 21. Crincoli V, Di Bisceglie MB, Scivetti M, Lucchese A, Tecco S, Festa F. Oral lichen planus: Update on etiopathogenesis, diagnosis and treatment. *Immunopharmacol Immunotoxicol*. 2011;33:11–20. [PubMed]
 22. Scully C, Carrozzo M. Oral mucosal disease: lichen planus. *Br J Oral Maxillofac Surg*. 2008;46:15-21.